

Diagnosis and Management of Alopecia Areata: A Saudi Expert Consensus Statement (2023)

وزارة الصحة
Ministry of Health

Contents

Abstract	3
Key Summary Points	3
Methodology	5
Clinical Features, Diagnosis, and Baseline Investigation	6
Assessment and Evaluation	7
Management of Alopecia Areata	10
Systemic Treatment	15
Follow Up After Treatment Initiation	20
Conclusion	20
References	34

Abstract

Alopecia Areata (AA) is a complex autoimmune disease manifesting as a chronic inflammatory disease characterized by non-scarring patches of hair loss over face, scalp, and body. Several treatments have been proposed for AA, but none are curative nor achieve a state of remission. The present consensus statement aims to present the evidence- and experience-based recommendations on the diagnosis and management of AA in Saudi Arabia. The Ministry of Health in Saudi Arabia has opted to initiate the meeting of a multidisciplinary group to discuss and concede on this topic. Eight dermatology experts and clinical pharmacists convened in eight consensus meetings. All content presented in this document was agreed upon by this working group, including diagnosis and severity assessment, prognostic indicators, and therapeutic options for AA. Special consideration was given to special patient populations including pediatric patients and patients with less frequent presentations of AA. Updates of the current recommendations will take place as new evidence evolves in the treatment of AA.

Key Summary Points

- The management of Alopecia Areata (AA) is influenced by various issues and can be approached differently by healthcare providers in their daily clinical practice.
- Numerous drugs and treatment methods have been proposed for AA, but none are curative. Currently available treatment options produce variable clinical outcomes, and none induce and sustain remission.
- This paper aims to offer current guidance, drawn from the best available evidence and the insights of expert dermatologists, for dermatologists and other healthcare professionals in Saudi Arabia who are responsible for managing patients with AA.
- The consensus development process was undertaken by a multidisciplinary group of eight experts, including six dermatologists and two clinical pharmacists.
- The success of AA treatment is achieved by meeting any or all of the following at week 24: Severity of Alopecia Tool (SALT) 75 reduction, SALT score 20 or less, achieving the Dermatology Life Quality Index (DLQI) of 5 or less. For Janus kinase inhibitors (JAKi), success of treatment should be reached maximum by week 36.

Introduction

Background and Definition

Alopecia areata (AA) is a chronic inflammatory disease characterized by non-scarring hair loss with the preservation of the hair follicle [1]. It is a complex auto-immune disorder mediated by a local surge of interferon gamma that collapses the hair follicle immune privilege and elicits an autoimmune response targeting exposed hair follicle autoantigens by the activation of autoreactive cytotoxic CD8+NKG2D+T cells [2-6]. Relapse rates in AA are high irrespective of therapy, and even with corticosteroid therapy relapse rates range between 33% and 75% [2, 7]. AA may present in both sexes and at any age, but the peak incidence is between 20 and 50 years of age [8, 9]. The prevalence of AA in Saudi Arabia was found to be between 2.3% and 5.2% in recent studies [10, 11], a prevalence higher than that in Western countries [11]. Patients in the Saudi population were also observed to present at younger ages [10, 11].

Purpose and Aim

The management of AA is influenced by various issues and can be approached differently by healthcare providers in their daily clinical practice. Numerous drugs and treatment methods have been proposed for AA, but none are curative. Currently available treatment options produce variable clinical outcomes, and none induce and sustain remission. The current consensus was developed to provide recommendations based on the best available evidence and the experience of expert dermatologists. It is intended to benefit general dermatologists and other healthcare providers who manage patients with AA in Saudi Arabia.

Scope

Topics reviewed in this document include the clinical and diagnostic criteria of AA, the assessment of disease severity, evaluation of associated comorbidities, and the various treatment options available, ranging from conservative management to systemic treatments, along with a treatment algorithm developed for clinicians to refer to as needed. Special considerations for the management of the pediatric population with AA and treatment options in other special populations are also discussed.

Target Patient Population

This consensus statement is created for the optimal management and treatment of pediatric and adult patients with AA.

Targeted Audience/End-Users

General dermatologists and other healthcare providers who manage patients with AA in their clinical practice.

Methodology

A multidisciplinary group of eight experts, including six dermatologists and 2 clinical pharmacists were chosen based on their extensive clinical and research expertise in treating AA. The Saudi Ministry of Health provided the necessary oversight and support throughout the entire process. A total of eight consensus meetings were conducted, six of which were held virtually, and the remaining two were conducted in-person.

During the first meeting, the participating members defined the objectives, scope, aim and target audience of the consensus statement. The work group identified three main topics of interest, which would serve as the sections for the review and consensus statement: (1) Clinical features, diagnosis, and baseline investigations (2) AA severity assessment and evaluation, (3) Management of AA and treatment options. Participating members were assigned to three workstreams based on their field of interest or expertise and they developed content for the consensus statement accordingly.

To guide the content development, the work group identified six international published consensus statements and disease management guidelines for AA. These documents served as the basis for the generation of this consensus, and they are as follows: the 2019 Italian Guidelines in diagnosis and treatment of alopecia areata, the 2019 Australian expert consensus statement, the 2020 Brazilian society of dermatology consensus on the treatment of alopecia areata, the Alopecia Areata Consensus of Experts (ACE) study parts I and II published in 2020 and 2021, and the 2022 Japanese guidelines [3, 12-16]. The reference lists from the identified guideline and consensus statements were scrutinized to identify further literature and research that would guide the content of the consensus statement. A manual search of relevant literature was further performed as needed.

Prior to the third and fourth meetings, a preliminary draft was shared with the participating members. During the meetings, the participating members discussed the content and the formal consensus methodology. The nominal group technique was used to agree upon the recommendations included in this consensus document. All members were entitled to vote on the clinical recommendations presented. A statement was considered consented when at least 75% of the voting experts agreed. The strength of the recommendation was not expressed.

The document was then compiled and included all consensus recommendations agreed upon during the expert group meetings. The final document was later shared with the expert work group for further revision and feedback. This article is based on previously conducted studies and does not contain any new studies with human participants or animals performed by any of the authors.

Clinical Features, Diagnosis, and Baseline Investigation

AA can manifest in several patterns. The most typical presentation is known as patchy alopecia which is characterized by the presence of single or multiple patches of localized hair loss. Other common presentations include alopecia totalis (AT) (complete loss of scalp hair) and alopecia universalis (AU) (total loss of body hair and scalp terminal hair) [14]. In rare cases, AA can present in other patterns, such as the ophiasis pattern (with band-like hair loss at the periphery of the occipital and temporal areas of the scalp), the ophiasis inversus-sisaiapho pattern (with band-like hair loss in the frontoparietal area), and AA incognita pattern (with diffuse hair loss and thinning simulating androgenetic alopecia and telogen effluvium) [14]. Another very rare variant is peri nevoid AA, which is characterized by hair loss surrounding a pigmented nevus. Some patients present with AA signs that are localized to specific hairy regions outside the scalp, such as the beard, eyelashes, and eyebrows [14].

Patients with AA do not usually report other associated symptoms. Cutaneous dysesthesia may be reported and may precede or be associated with hair loss [14] and is a sign of active disease [15]. Patients might also present with scalp itching and tingling at the site of hair loss [15]. On physical exam, the skin underlying the affected patches usually appears normal and smooth and may rarely exhibit pink discoloration. White hairs may initially be spared in AA. In cases of extensive AA this leads to a phenomenon called canities subita (sudden greying of the hair) [14]. Fine white vellus hairs may also be a sign of hair regrowth [14].

AA diagnosis is mainly clinical and is established through physical examination and trichoscopic findings [15]. This clinical diagnosis is supported by obtaining a detailed family history for autoimmune disorders (including but not limited to thyroid disorders, atopy, and celiac disease) [14]. The activity of hair loss can be determined by noting the presence of “exclamation point hairs” at the periphery of bald areas and the qualitative positive AA “hair pull test” [17]. Scalp biopsy is not

recommended unless the diagnosis is not clear. The characteristic clinical features of AA include intact follicular ostia visualized either directly or through dermoscopy, positive pull test, complete loss of terminal hairs in at least one patch of hair loss, and the absence of signs of active follicular inflammation (such as perifollicular erythema, scaling, pustules, etc.) [17]. Yellow and/or black dots at the ostia on dermoscopy, trachyonychia, fine pitting of the nails, and 20-nail dystrophy are considered supportive features for the diagnosis of AA [17].

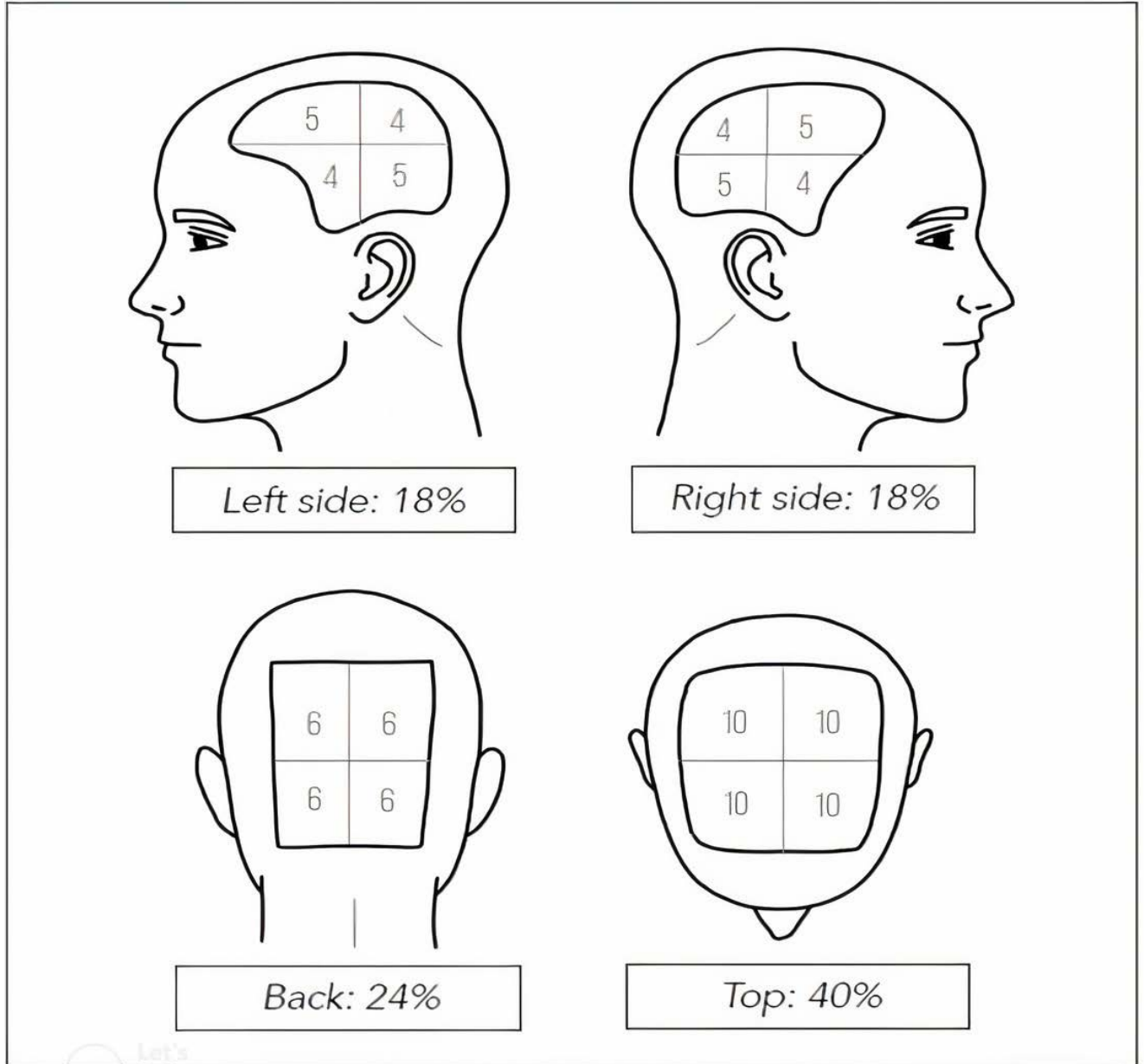
Assessment and Evaluation

Assessment Tools

Assessment of AA must be conducted in the initial patient encounter and during follow up visits. There are multiple severity assessment tools to assess AA disease extent, these include the following: Severity of Alopecia Tool (SALT), SALT II, Alopecia Density and Extent (ALODEX), Alopecia Areata Progressive Index, and quality-of-life measures including Dermatology Life Quality Index (DLQI) and Alopecia Areata Symptom Impact Scale (AASIS). A more recent scoring scale that has been developed in 2022, the AA Scale which is designed specifically for use in clinical practice captures broader features of the disease [17, 18]. Eyelashes and eyebrows can be assessed using the Clinician-Reported Outcome (ClinRO) and Patient-Reported Outcome (PRO) [19]. Consensus was achieved on using the SALT score as a measure of disease severity in children and adults [17], and ClinRO for eyebrows and eyelashes involvement assessment [19].

SALT I scoring visual aid was first published in 1999 and updated in 2004. It provides a visual guide to estimate the area of terminal hair loss in each of the four quadrants of the scalp and then generate the percentage of scalp hair loss and SALT score by adding up the estimates from the four quadrants (**Figure 1**). The SALT score allows clinicians to estimate the total area of the scalp with loss of terminal hair [20, 21].

Figure 1. Visual aid for the estimation of percent hair loss and determine SALT score (Reproduced from [20, 21])



Drawing credits: Fatimah Alowirdi, Dermatology Resident, King Abdulaziz Medical City, Riyadh, SA.

Laboratory Evaluation

Laboratory evaluation is warranted upon clinical suspicion of an underlying disorder, and there is no set of tests that is to be routinely ordered for patients presenting with AA [15]. When there are clinical signs of a tinea capitis infection, fungal microscopy should be performed. Moreover, when patients present with clinical signs and symptoms that point towards another underlying etiology for hair loss, the clinician may opt to perform blood tests as needed (complete blood cell count; renal and liver function) and to screen for other diseases (such as autoimmune diseases, connective tissue disease, celiac disease, pernicious anemia, and diabetes). Viral serology maybe useful in patients who present with clinical symptoms suggestive of a triggered alopecia areata episode. Measuring early morning cortisol levels is not indicated in patients who believe that stress may have triggered their current episode. In preparation for the initiation of systemic treatment for AA patients, laboratory investigations must be done and are identical to those performed in other dermatological diseases [15].

Psychosomatic evaluation

Identifying patients and families who need psychological support is a fundamental component of AA management. Children, adolescents, and adults with AA are at increased risk for psychiatric comorbidity, particularly mood and anxiety disorders. This is especially the case in patients with severe or recalcitrant disease. Parents of children affected by AA may also experience anxiety and depression [22-24].

Prognosis and Prognostic Indicators

AA is a chronic disease with an unpredictable course as previously indicated. Spontaneous remission of a single lesion is estimated at 70% in the first year, while around 7% progress to AT or AU [13]. Potential prognostic indicators for poor outcomes include the following:

1. Childhood onset of AA, particularly those presenting at less than 6 years of age [25]
2. Severity of disease at onset in adults (*this is the most important negative prognostic indicator*) [26]
3. Duration of active disease; prognosis is worse when AA persists beyond 5 years (2% potential for hair regrowth) and disease can be irreversible if it persists for 10 years (*However, this is not a contraindication for a trial of therapy, successful cases of hair regrowth have been seen in patients with active AA with disease duration exceeding 10 years*) [15]
4. AA phenotype; especially ophiasis pattern [15, 26]

5. Involvement of the eyebrows, eyelashes, and non-scalp hair loss [15]
6. Nail involvement; nail pitting and trachonychia suggest an increased risk of developing AT/AU and worsen prognosis overall for AA [27]
7. Prior and/or current atopic conditions, including atopic dermatitis, asthma, hay fever/allergic rhinitis, and/or allergic conjunctivitis [17]
8. Trisomy 21 (Down syndrome); this syndrome is associated with an increased prevalence (9%) and severity of AA, it is estimated that 40% of patients with trisomy 21 will develop AT/AU [28]

The emergence of AA may also be influenced by systemic and immunological factors. Examples of such factors include personal history of diabetes mellitus, peptic ulcer, bilateral oophorectomy, hypertension, atherosclerosis, Grave's disease, and myxedema. However, these are not confirmed to be poor prognostic factors [12, 15]. Type 1 diabetes and other autoimmune disorders such as celiac disease and rheumatoid arthritis have been shown to have a genetic association with AA, suggesting common molecular pathways in their pathogenesis [29, 30]. Family history of AA has not been proven to be a poor prognostic indicator [15].

Management of Alopecia Areata

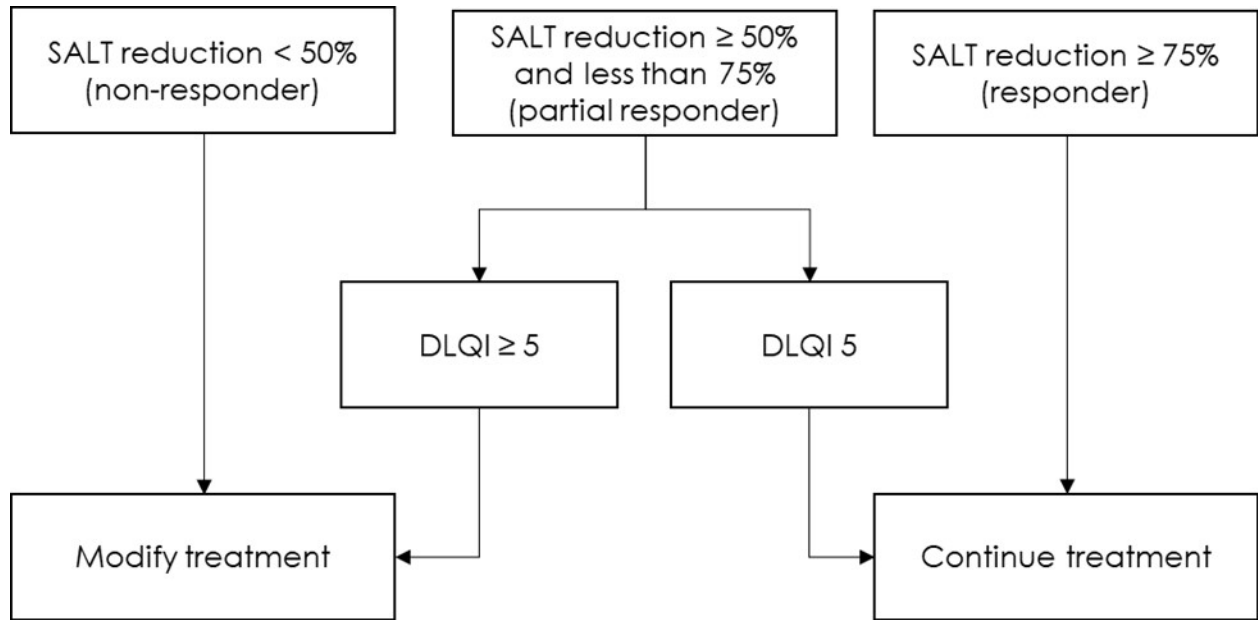
Treatment Goals

Treatment of AA aims to restore hair density and improve the psychological wellbeing of impacted patients. Success of treatment is reached by meeting any or all of the following at week 24 (Figure 2) [17]:

- A) SALT 75 reduction
- B) SALT score 20 or less
- C) Achieving DLQI of 5 or less

For JAK inhibitors, success of treatment should be reached maximum by week 36 [31, 32].

Figure 2. Use of treatment goals to guide therapy



Conservative Management

Reassurance can be enough for patients with limited stable disease [12]. Cosmetic camouflage options can be suggested in some cases [13]. Cosmetic camouflages are available in different forms such as hair fibers, sprays, waxes, tattoos, trichopigmentation, and pigmented powders (can be applied on the scalp and eyebrow area). Patients can also use wigs, false eyelashes, and eyebrow prostheses [13, 14].

Non-Pharmacologic Treatment

Photochemotherapy

Psoralen plus ultraviolet A (PUVA) is not recommended as a treatment option of AA due to the risk of large cumulative doses of UVA on the long term, as AA is a chronic disease. This increases the risk of cutaneous malignancy [33]. UVA-1, which has greater penetration into the skin and is more effective, may be an alternative option in the treatment of AA [34].

Excimer laser/Excimer light

As previously mentioned, AA is considered a T-cell mediated autoimmune disorder. The 308-nm excimer laser and excimer light are thought to have immunosuppressive properties by inducing T-cell apoptosis. Therefore, they can be used as an alternative treatment and as an adjuvant therapy for

acute/subacute resistant patches of AA [35]. The side effects include mild erythema, contact eczema, blistering, pruritus, and hyperpigmentation [36].

Intralesional Treatment

Intralesional corticosteroid therapy

The treatment algorithm for AA is shown in Figure 3. Intralesional corticosteroids are the standard of therapy for patients with clinical evidence of active inflammation [13]. Positive pull test, black dots, and exclamation point hairs can be used as indicators of active inflammation [16]. The most commonly used corticosteroid is triamcinolone acetonide (TAC). The recommended dose for scalp patchy AA is 2.5 mg/ml at higher volume of 8 ml per session [37].

For the procedure, TAC is diluted with saline then 0.05 – 0.1 mL (per injection) is injected into the dermis or upper part of subcutaneous tissue. Injections are optimally spaced of 0.5-1 cm apart, and a time interval of 4-6 weeks must separate the sessions [13]. Caution is required especially near the frontal hairline as the risk of atrophy is higher [16]. Lidocaine can be mixed with TAC. However, some components of the lidocaine vehicle can increase the risk of flocculation of the drug leading to more atrophy. This procedure is uncomfortable to the patients; therefore, it is recommended to apply local anesthetics, cooling, or vibration to the area prior to the procedure to minimize discomfort. Needle free devices are another option for this procedure. Treatment using TAC should be discontinued if no improvement is seen within six months [13]. Side effects of TAC include pain, bleeding, headaches, systemic absorption, dyspigmentation, reversible skin atrophy (lasting a few months), and rarely, anaphylaxis [13].

Topical Treatment

Topical corticosteroid therapy

Topical corticosteroid therapy is the first-line topical treatment for scalp AA in children and adults who refuse intralesional corticosteroid therapy (**Table 1**) [14]. The recommended topical corticosteroid for scalp patchy AA in adults is ultrapotent topical corticosteroid, such as clobetasol propionate foam [37], cream, or ointment. This treatment is more effective under occlusion (it also results in more side effects in this situation) [13]. For children less than 10 years of age, a less potent corticosteroid, such as mometasone, is preferred [37]. These medications should be applied daily for a period of six weeks to six months. Complete regrowth of hair is the indication for treatment

discontinuation [16]. Common side effects are folliculitis, acneiform eruption, atrophy, dyschromia, and telangiectasia. Adrenal suppression is less common [13]. After hair regrowth, tapering of potent topical corticosteroids should be considered based on each patient's individual situation and the physician's expertise and clinical judgement [14].

Minoxidil

The mechanism of action of Minoxidil is still not known. Some theories regarding the mechanism of Minoxidil propose that this drug leads to vasodilation, potassium channel opening, angiogenesis, and induction of follicular dermal papilla proliferation. Minoxidil acts by increasing the duration of the anagen phase of the hair cycle and, therefore, it can increase the length and thickness of the new hair [13]. In adults, 5% Minoxidil applied once or twice daily is preferred [13].

The use of 5% Minoxidil alone is insufficient in AA [13]. For this reason, Minoxidil is used as an adjuvant therapeutic agent along with other treatments, and it may help maintain hair growth induced by other treatments [37]. Minoxidil is easy to use and has minimal side effects (mainly mild dermatitis and itching). Less than 5% of the patients may grow unwanted hair [37].

Topical Immunotherapy (TIT)

TIT is used in extensive chronic AA. TIT includes diphenylcyclopropanone (DPCP) and squaric acid dibutyl-ester (SADBE). The mechanism of action is not fully understood. The proposed theory is that TIT allow the follicle to recover through induction of inflammatory process in a place other than the hair bulb [13]. TIT agents cause allergic contact dermatitis [14, 37].

DPCP is the most used TIT for treating AA. Its success rate ranges from 30-48%, with an overall response rate of 72.2% across all grades [13, 37, 38]. However, there is limited evidence supporting its effectiveness in cases of extensive resistant AA, and further well-designed randomized controlled trials are needed to establish its efficacy [39]. It is only available at compounding pharmacies as it should be formulated with acetone and kept in an amber bottle to protect it from light [13]. Patients need to undergo sensitization before starting the treatment. During the sensitizing phase, a small amount of 2% DPCP is applied with a cotton swab on a barely visible area of 4 cm diameter, such as the scalp area behind the ear [13]. Patients are instructed to cover the scalp and avoid light and water exposure in the first 48 hours [13, 37]. One week after sensitization is performed, 0.001% DPCP is applied by the physician or nurse unilaterally with an increase in the concentration on weekly basis

until the effective (ideal) concentration for the patient is reached. This ideal concentration can be identified by the presence of mild tolerable dermatitis that lasts 36 hours. Once there is response to the treatment on one side, both sides can be treated [37]. After hair regrowth, and during the weaning phase, the frequency of application is reduced to biweekly then monthly and finally the treatment is discontinued [13].

For patients who fail to respond to DPCP, therapy with SADBE may be attempted. It is important to note that treatment with these agents should not be discontinued abruptly, as this can increase the risk of relapse [37].

TIT sensitizers are contraindicated in pregnant women [37]. Common side effects include pigmentary changes and vitiligo particularly in patients with dark skin [14], severe eczema, blisters, lymph node enlargement, and flu-like symptoms [13].

Anthralin

Anthralin was historically used for psoriasis [14]. Anthralin reduces the inflammation of the hair follicle by diverting it from the bulb and causes irritant dermatitis. It has no systemic side effects; therefore, it can be used in children [13, 14]. Anthralin can be found in concentrations from 0.5% to 2% [14].

The drug is applied on daily basis for 30 minutes. It is applied on the affected area and up to 1 cm into the healthy area. Every three days the time of application is increased by 15 minutes until a maximum of two hours is reached. The patient should wash the area thoroughly to remove the product. The initial response is expected in three months with complete response in 15 months [13]. The combination of Anthralin and DPCP has been reported to be more effective than treatment with DPCP alone [14].

Another treatment method includes the application of Anthralin (concentration 0.5 or 1% cream). The cream is applied for around 20 to 30 minutes daily. Contact time with the affected skin is to be increased by 10 minutes biweekly to a maximum time of one hour or to the contact time that causes mild dermatitis. Alternatively, Anthralin can be started at lower concentrations (0.1%). In this case, the patient would apply the cream to the scalp area for 10 to 20 minutes and then gradually increase contact time until having anthralin on the affected area overnight is tolerable [14].

The frequent application of Anthralin can cause follicular ostia pigmentation. This can appear as black dots which can be differentiated by dermoscopy as brown pigmentation at the edge of the ostium, while the pigmentation in the black dots is in the center of the ostium [13].

Lack of pigmentation can be a sign of treatment failure. Possible causes for failure are inappropriate application, inadequate application time, or low-quality preparation [13]. The fact that anthralin can stain hair, skin, and clothes might limit its use in fair-haired patients [14].

Topical calcineurin inhibitors

Topical calcineurin inhibitors can be used to treat scalp, eyebrow, or beard AA. They are not effective as monotherapy and are usually used with other agents [16]. Topical tacrolimus is used for the treatment of AA especially in the face region and in the pediatric population. It is applied twice daily for 6 months. Pimocrolimus cream (1%)'s efficacy in AA was not proved [16]. Overall, the data available on these medications is lacking and their routine use in AA is not recommended [13].

Systemic Treatment

Eligibility Criteria

There are no set universal indications for initiating systemic treatment for AA. However, possible indications for systemic treatment include (between 18 – 50 years old) [12, 16, 25]:

1. Extensive disease (SALT score \geq 50)
2. SALT score $<$ 50 and DLQI score \geq 10
3. Rapid progression of hair loss to \geq 50% within 4 months of disease onset
4. All lesions that have failed a 6-month trial of topical or serial intralesional corticosteroid.
5. Patients with a large or multiple lesions of AA, that cannot be easily managed with intralesional therapy due to the discomfort associated with the number of injections required, and patients who experience dermal atrophy following intralesional corticosteroid or side effects following topical steroid use.
6. Significant facial involvement (eyebrows or eyelashes) + SALT 50 or above (any age within SFDA approval)

Systemic Treatment Options

Systemic corticosteroids

Prednisolone (prednisone) is the preferred choice when systemic corticosteroid therapy is to be instituted and is optimally administered daily (Table 2). Systemic corticosteroids are a suitable treatment option for severe AA in adolescents aged 13 to 18 years. Prednisolone is started initially at a dose of 0.4 to 0.6 mg/kg/day. It is eventually gradually tapered over a minimum 12-week duration for durable remission to be achieved. A tapering duration of more than 12 weeks may be needed to achieve durable remission in adult patients [16].

In adults with extensive AA, dexamethasone oral pulse can be used starting at 5mg/day two days a week for at least 12 weeks. In one study, 63% of 30 patients had an excellent response with oral pulse therapy. Mild side effects were noted in a quarter of the patients [40].

Cyclosporine

Cyclosporine is an effective treatment option in adults with severe AA. It is optimally dosed at 3 to 5 mg/kg/day, with a treatment duration that does not exceed 6 to 12 months [16].

Methotrexate

Methotrexate can sometimes be used as monotherapy in severe AA. In adults, dosing is 15 to 20 mg weekly. Methotrexate monotherapy is also an option in adolescents aged 13 to 18 years with severe cases of AA. In the latter patient population, the target dose is 0.4 mg/kg/week [16].

Azathioprine

Azathioprine is another treatment option for AA. This drug is usually started at a low dose of 0.5–1 mg/kg daily to reduce the risk of gastrointestinal upset. It is gradually titrated every 4–6 weeks reaching a maximum dosing rate of 2–3 mg/kg and this titration is done based on the response recorded and patient tolerance to the drug [12].

Sulfasalazine

Sulfasalazine can be considered for the therapy of persistent AA [41]. This drug is initially dosed at 0.5 g twice daily for 1 month, then 1 g twice daily for 1 month, and eventually dose reaches 1.5 g twice daily for 4 months. In one study, the relapse rate was 45.5%, and 32% of patients suffered from adverse effects (gastrointestinal distress, rash, headache, and laboratory abnormalities) [42, 43].

Due to lower efficacy of sulfasalazine and azathioprine, there is group consensus that these medications should not be used as first line by the treating physician and are to be used only as an alternative therapy [43, 44].

Janus kinase (JAK) inhibitors

JAK inhibitors are small molecule drugs with a few currently in the pipeline for treatment of moderate to severe AA. [45].

Options for JAK inhibitor treatment in AA include the following:

1. Baricitinib (JAK 1/2 inhibitor), which has recently been approved by the SFDA for treatment of severe AA in adults, dose 2 to 4 mg orally once daily.
2. Ritlecitinib (JAK₃ selective inhibitor), which has recently been approved by the FDA for individuals aged 12 years and older dosed at 30mg or 50mg once daily [46].
3. Tofacitinib (JAK 1/3 inhibitor), dosed at 5 mg orally twice daily to 10 mg twice a day in severe alopecia areata [47-49].
4. Ruxolitinib, (JAK 1/2 inhibitor), dosed at 20 mg orally twice daily. In an open-label pilot study, 75% of patients achieved at least 50% hair regrowth after three to six months of therapy [50].

Side effects of JAK inhibitors include infections, viral reactivation, dyslipidemia, transaminase changes, leukopenia, headache, gastrointestinal complaints, thromboembolic events in high-risk patients, fatigue and weight gain and acne [50-52]. Long-term safety data is still limited [53].

Generally, the response to the treatment with JAK inhibitors does not correlate with disease severity nor duration, and there are no predictors of response up to this date [53].

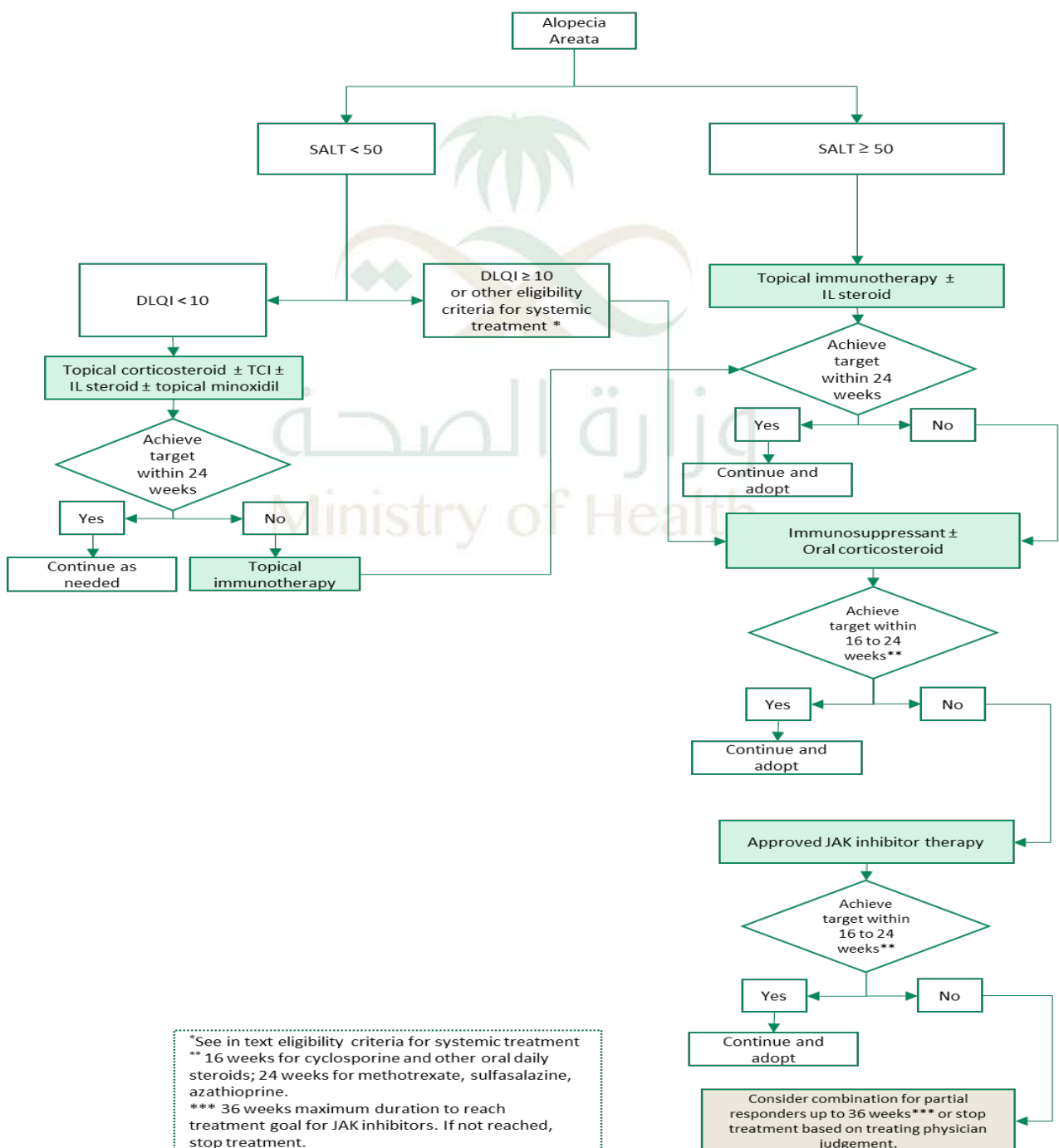
Combination of systemic agents

Methotrexate (10-25 mg per week) can be useful when used in association with systemic steroids (clinical response rate of 63%) [54]. The combination of cyclosporine (2.5 to 5 mg/kg/day) with low-dose corticosteroids (methyl prednisone started as 20 mg/day then subsequently tapered to 2 mg/day) has adequate efficacy and minimal toxicity for the treatment of severe AA [55]. Tofacitinib 5 mg twice daily can be combined with systemic steroids in resistant cases of AA [56]. Moreover, the combination of tofacitinib 5 mg twice daily and low dose oral minoxidil (2.5 mg once daily for women and 2.5 mg twice a day for men) has been shown to produce positive outcomes, with a low incidence

of adverse effects [57]. The treating physician may consider a similar combination with baricitinib, however further evidence is necessary to determine the best specific combination.

Finally, simvastatin (40 mg) can be combined with ezetimibe (10 mg) orally and administered daily for 3 months as an alternative treatment for recalcitrant AA [58], but data on this treatment option is still limited and controversial [59].

Figure 3. Alopecia Areata Treatment Algorithm



Treatment in Special Situations

AA in Children

In children with AA, topical corticosteroids, preferably of medium to high potency (mometasone 1% to clobetasol 0.05%), are used as the first therapeutic option. When there is contraindication or lack of response to topical corticosteroids, anthralin, DPCP, or minoxidil may be used [13].

The combination of two or all three of these therapeutics is considered the second-line management. Systemic therapy is considered a third-line management option in children below the age of 12 years. In the absence of data confirming that systemic therapy reduces the risk of subsequent development of AT or AU, there is no consensus on the use of systemic therapy in children below the age of 12 years [12]. A decision can be taken by an experienced dermatologist on case-by-case basis.

AA in the Beard Area

Topical or intralesional corticosteroid therapy are the treatments of choice for AA affecting the beard. However, there is a higher risk of atrophy associated with the use of corticosteroids in this area. Triamcinolone 2.5mg/ml is the most suitable concentration for this area. Topical minoxidil and anthralin may also be considered [13]. There is no consensus on the usage of calcineurin inhibitors for AA in the beard.

AA in the Eyelashes and Eyebrows

With respect to eyelash hypotrichosis, the treatment of choice is analogues of prostaglandin F_{2a} (latanoprost or bimatoprost) in solution used once daily. This treatment should be used for a minimum of 12 months to be able to assess its response. It is important to note that there is a risk of eyelid hyperpigmentation and darkening of the iris with this treatment option [12-14].

With respect to AA in the Eyebrows, treatment options include topical corticosteroid of medium potency in cream or intralesional triamcinolone (2.5 mg/mL). Alternatively, 0.03% bimatoprost or topical minoxidil can be used [13]. Systemic treatment may be considered after failure of topical and intralesional modalities in case a patient reaches a ClinRo score of 2 or more.

Follow Up After Treatment Initiation

The period between follow up visits is dependent on the treatment regimen used. Patients on DPCP should be assessed weekly or biweekly, and those treated with intralesional corticosteroids need to be followed up every 4 – 6 weeks, while patients using topical treatment are usually assessed every two to three months [13].

Patients treated with systemic corticosteroids agents should be weaned over a duration of at least three months. Patients on steroid-sparing agents should continue treatment for 3-6 months after complete remission, and tapering can be attempted during that period. The process of weaning the medication helps in decreasing the risk of relapse. Nevertheless, relapse can occur during weaning. In the case of patients who are taking an adequate dosage of systemic agents who develop major relapses (multiple new patches), treatment should be discontinued, and other treatment options considered. Relapses can be treated by dose escalation, the use of intralesional triamcinolone acetonide, or a short course of systemic corticosteroids [12].

Response to treatment should be assessed clinically through history taking, assessing hair-shedding severity, obtaining serial photography of the affected areas, measuring the SALT score and quality of life indexes [12]. Dermoscopic photos of the affected areas are recommended as well [16]. These assessment tools are utilized to correlate the response observed in the last visit to the situation in the initial visit status (baseline). A SALT reduction of 75 (75% improvement in SALT) is an appropriate goal for a successful treatment regimen. However, increased hair shedding, positive pull test, especially at the edge of the patches, as well as exclamation mark hairs and black dots on dermoscopy, are indicators of active disease [12].

Conclusion

AA is a condition that impacts patients from all ages and can present in many ways. It is commonly encountered by general dermatologists and other healthcare providers. AA is a psychologically distressing disease and successful management is key to improve the quality of life of those affected. An adequate clinical assessment and evaluation, and a understanding of the treatment options available, are essential for a healthcare provider to manage this disease. This document serves as a guide for clinical practitioners to refer to and take the best approach in treating their patients with AA. An individualized plan should always be considered for patients with AA to achieve the best outcomes possible.

Table 1: Topical therapies for alopecia areata

Pharmacological Category	Drug Name	Dosage Form	Strength	SFDA registration	Authority Approval	Medication Safety	
						Pregnancy ^a	Black Box Warning
Corticosteroids (Class I Very potent)	1. Clobetasol propionate	- Cream - Ointment - Cutaneous suspension	0.05%	Yes	SFDA, FDA, EMA (Off-label)	Category B ₃	None
	2. dexamethasone(Desoximetasone)	- Cream	0.25%	No	SFDA, FDA, EMA (Off-label)	Category B ₃	None
Corticosteroids (Class II Potent)	3. Mometasone Furoate	- Cream - Ointment - Cutaneous suspension	0.10%	Yes	SFDA, FDA, EMA (Off-label)	Category B ₃	None
	4. Triamcinolone acetonide [56, 57]	- Solution	10mg/ml	Yes	SFDA (Off-label), FDA, EMA	Category A	None
Corticosteroid (Class III Moderate)	5. Betamethasone	- Solution	0.05%	No	SFDA, FDA, EMA (Off-label)	Category B ₃	None
	6. Betamethasone Dipropionate	- Ointment - Cream	0.05% 0.05%	Yes			
	7. Betamethasone valerate Scalp Application	- Lotion	0.1%	Yes			
Immunosuppressant Calcineurin Inhibitor	8. Tacrolimus	Ointment	0.03%, 0.1%	Yes	SFDA, FDA, EMA (Off-label)	Category B ₃ ^b	Malignancy (e.g., skin, melanoma and lymphoma)
	9. Pimecrolimus	Cream	1%	Yes			
Vasodilators	10. Minoxidil	Solution Foam	2%, 5% 5%	Yes No	SFDA, FDA, EMA	There are no adequate and well-controlled studies in pregnant women.	None

Immunosuppressant	11. Anthralin	Cream	0.5 % & 1%	No	SFDA, FDA, EMA (Off-label)	Category B ₂	None
Topical immunosensitizer	12. Diphenylcyclopropanone DPCP Squaric acid dibutyl-ester SADBE	Powder	2%	No	SFDA (Off-label) FDA: Approved EMA: Off-label	Unknown but not recommended	None
Prostaglandins	13. Bimatoprost 14. Latanoprost	Solution/Drops Solution/Drops	0.1 mg/ml 0.005 %	Yes	SFDA, FDA, EMA (Off-label)	Category C ^c	None
JAK inhibitors	15. Ruxolitinib	Cream	1.5%	No	SFDA, FDA, EMA (Off-label)	There are no adequate and well-controlled studies in pregnant women.	None

Tacrolimus (Topical) crosses the human placenta and is measurable in the cord blood, amniotic fluid, and newborn serum following systemic use. Tacrolimus (systemic) consider as category C*

^c Beta-adrenergic blocking agents may cause pharmacological effects such as bradycardia in the fetus and newborn infant

Table 2: Systemic treatment options for alopecia areata

Pharmacologic Category	Drug Name	Strength	Authority approval	Monitoring ^a		Medication safety	
				Baseline monitoring	Follow-up monitoring	Pregnancy ^b	Contraindications
Immunosuppressant Agent (Calcineurin Inhibitor)	Cyclosporine [58]	25 mg, 50 mg, 100 mg Capsules	SFDA: Off-label FDA: Off-label EMA: Off-label	CBC with differential LFT RFT, TB testing, HCG, HIV, BP, UA with microscopic analysis, Fasting lipid profile, Electrolytes (Mg, K), Uric acid	BP, CBC with differential RFT, lipids, Electrolytes (Mg, K), Uric acid	Category C ^c	<ul style="list-style-type: none"> - Known hypersensitivity to cyclosporine or any ingredient in the formulation - Comorbid RA or Psoriasis + abnormal renal function, uncontrolled hypertension, or malignancies - Concurrent therapy with MTX or other immunosuppressive agents, coal tar, PUVA, UVB, or other radiation (in the management of psoriasis)

Immunosuppressant Agent (Antimetabolite)	Methotrexate [59]	2.5 mg Tablet	<p>SFDA: Off-label</p> <p>FDA: Off-label</p> <p>EMA: Off-label</p> <p>CBC with differential, BP, RFT, LFT UA with microscopic analysis, fasting lipid profile Electrolytes (Mg, K) Uric acid, TB testing, pregnancy test and HCG</p>	<p>CBC with differential, BP, RFT, LFT Fasting lipid profile Electrolytes (Mg, K) Uric acid, TB testing, pregnancy status, HCG, and neurotoxicity assessment</p>	Category D ^d	<ul style="list-style-type: none"> - Pregnancy: in pregnant women with psoriasis or RA, use in treatment of neoplastic diseases only when potential benefit outweighs risk to fetus - Breastfeeding - Excessive alcohol consumption, alcoholic liver disease, or other chronic liver disease in patients with psoriasis or RA - Immunodeficiency - Preexisting blood dyscrasias (e.g., bone marrow hypoplasia, leukopenia,
---	-------------------	------------------	--	--	-------------------------	---

Pharmacologic Category	Drug Name	Strength	Authority approval	Monitoring ^a		Medication safety	
				Baseline monitoring	Follow-up monitoring	Pregnancy ^b	Contraindications
							thrombocytopenia, clinically important anemia)
							- Known hypersensitivity to MTX
							- Known hypersensitivity to azathioprine or any ingredient in the formulation
Immunosuppressant Agent (Purine Antimetabolite)	Azathioprine [60]	50 mg Tablet	SFDA: Off-label FDA: Off-label EMA: Off-label	LFT, RFT, CBC/differential/platelets HBV/HCV testing, TB testing, HCG if indicated Pulmonary function tests if indicated	LFT, RFT, TB testing, HCG as indicated	Category D ^e	- Pregnancy - Patients previously treated with alkylating agents (cyclophosphamide, chlorambucil, melphalan), because of prohibitive risk of neoplasia

Pharmacologic Category	Drug Name	Strength	Authority approval	Monitoring ^a		Medication safety	
				Baseline monitoring	Follow-up monitoring	Pregnancy ^b	Contraindications
Immunosuppressant Agent (Antineoplastic antibiotic)	Mycophenolic acid [61]	250mg, 500mg, 180mg, 360mg	SFDA: Off-label FDA: Off-label EMA: Off-label	RFT, LFT, HBV/HCV, CBC/differential/platelets TB testing HCG if indicated	LFT, RFT, CBC/differential/platelets TB testing, HCG as indicated	Category D ^f	- Known hypersensitivity to mycophenolate sodium, mycophenolic acid, mycophenolate mofetil, or to any of its excipients
Immunosuppressant Agent (Anti-inflammatory)	Sulfasalazine [62]	500mg Tablet	SFDA: Off-label FDA: Off-label EMA: Off-label	CBC with differential, LFT	Monitor for blood dyscrasias, photosensitivity, gastrointestinal disturbance, anemia, jaundice, hematuria, CNS changes, rash or other skin reaction.	Category A	- Known hypersensitivity to sulfasalazine, its metabolites, sulfonamides, or salicylates. - Intestinal or urinary tract obstruction - Porphyria

Pharmacologic Category	Drug Name	Strength	Authority approval	Monitoring ^a		Medication safety	
				Baseline monitoring	Follow-up monitoring	Pregnancy ^b	Contraindications
Janus kinase (JAK) inhibitors Nonselective JAK1 JAK3	Tofacitinib citrate [63]	5 mg Tablet	SFDA: Off-label	Hematological parameters	Blood counts	Category D ⁹ Use is not recommended	- No known contraindications - Warning : Hypersensitivity ,Gastrointestinal Perforations , Avoid use with live vaccine , Thrombosis, Serious infections , TB ,higher rate of
			FDA: Off-label EMA: Off-label				
Janus kinase (JAK) inhibitors Nonselective JAK1 JAK2	Ruxolitinib phosphate [64]	5 mg, 15 mg, 20 mg, 25 mg Tablet	SFDA: Off-label FDA: Off-label EMA: Off-label	CBCs as clinically indicated and adjust dosage as required.	lipid parameters renal function, hepatic function	Category C	

Pharmacologic Category	Drug Name	Strength	Authority approval	Monitoring ^a		Medication safety	
				Baseline monitoring	Follow-up monitoring	Pregnancy ^b	Contraindications
Janus kinase (JAK) inhibitors Nonselective JAK1 JAK2	Baricitinib [65]	2 mg ^{k,4} mg Tablet	SFDA : approved for adult with sever AA FDA : approved for adult with sever AA EMA: approved for adult with sever AA	CBC with differential, LFT, Viral hepatitis, Latent or active TB	CBC with differential, Lipid profile, LFT signs and symptoms of TB, Skin examinations	Category D ^h Should be not used, Placental transfer of baricitinib may be expected based on molecular weight	lymphoma and lung cancer .

Pharmacologic Category	Drug Name	Strength	Authority approval	Monitoring ^a		Medication safety	
				Baseline monitoring	Follow-up monitoring	Pregnancy ^b	Contraindications
Janus kinase (JAK) inhibitors Selective JAK ₃	Ritlecitinib [66, 67]	10 mg, 30 mg, 50 mg Tablet	SFDA: No FDA: Yes EMA: in Progress	CBC with differential (baseline, every 2 to 4 weeks until dose stabilized), Lipid profile, LFT signs and symptoms of TB, Skin examinations	CBC with differential, Lipid profile, LFT signs and symptoms of TB, Skin examinations , Monitor hepatitis B viral load , renal function	Use of ritlecitinib in pregnant patients is not recommended	

Antilipemic Agent, HMG-CoA Reductase Inhibitor	<i>Ezetimibe / Simvastatin</i> [68]	10 mg/20 mg 10 mg/40 mg Tablet	SFDA: Off-label FDA: Off- label EMA: Off-label	Lipid panel (total cholesterol, HDL-C, LDL-C, TG), Hepatic transaminase levels, CPK	lipid panel	Category D ⁱ	<ul style="list-style-type: none"> - Known hypersensitivity to ezetimibe, simvastatin, or any component of this medication - Coadministration with strong CYP_{3A4} inhibitors, gemfibrozil, cyclosporine, or danazol - Active liver disease or unexplained persistent elevations in hepatic transaminases - Pregnancy or use in women who may become pregnant - Breastfeeding
--	--	--	---	---	-------------	-------------------------	---

Pharmacologic Category	Drug Name	Strength	Authority approval	Monitoring ^a		Medication safety	
				Baseline monitoring	Follow-up monitoring	Pregnancy ^b	Contraindications
Vasodilators	<i>Minoxidil</i> [69]	2.5 mg 5 mg Tablet	SFDA: Off-label FDA: Off-label EMA: Off-label	BP standing and sitting/supine, Assessment for signs/symptoms of pericardial effusion, cardiac tamponade, angina, and heart failure, Fluid and electrolyte balance and body weight		Category C ^j Use is not recommended	- Pheochromocytoma - Known hypersensitivity to minoxidil or any ingredient in the formulation

Corticosteroid	<i>Prednisone</i> [70]	10 mg, 20 mg Tablet	Off label	BP; weight; serum glucose; electrolytes; creatinine kinase; growth in pediatric patients; presence of infection, bone mineral density; assess HPA axis suppression	BP, chest x-ray, eye examination, linear growth velocity in pediatric patients	Category A	<ul style="list-style-type: none"> - Known hypersensitivity to prednisone, any ingredient in the respective formulation, or any other corticosteroid - Systemic fungal infections - Concurrent administration of live or live-attenuated vaccines in patients receiving immunosuppressive doses of corticosteroids - If substantial dosage is received during pregnancy, carefully observe
----------------	---------------------------	---------------------------	-----------	---	---	------------	--

Pharmacologic Category	Drug Name	Strength	Authority approval	Monitoring ^a		Medication safety	
				Baseline monitoring	Follow-up monitoring	Pregnancy ^b	Contraindications
							infant for signs of hypoadrenalism

^a Physicians should consult the approved product monographs within their institution's formulary for each drug for details concerning patient monitoring and frequency of follow-up and testing; ^b Based on the Australian categorization system for prescribing medicines in pregnancy (AU TGA); ^c cyclosporine may cause immunosuppression in the infant; ^d MTX Cytotoxic agents can produce spontaneous abortion, fetal loss and birth defects; ^e azathioprine has been associated with a slightly increased risk of fetal malformations, neonatal immunosuppression and bone marrow suppression in the infant; ^f Mycophenolic acid inhibits nucleic acid synthesis and may cause fetal malformations/death. Congenital malformations, including ear malformations i.e. abnormally formed or absent external/middle ear, have been reported in children of patients exposed to mycophenolate mofetil in combination with other immunosuppressants during pregnancy; ^g This drug is embryotoxic in both pregnant rats and rabbits, and teratogenic when administered to pregnant animals; ^h Based on the mechanism of action, baricitinib is suspected to affect early embryonic development when administered during pregnancy. Baricitinib has been shown to cause embryofetal lethality and fetal malformations in pregnant rats or rabbits; ⁱ Cholesterol and other products of the cholesterol biosynthesis pathway are essential components for fetal development, including synthesis of steroids and cell membranes. Because of the ability of inhibitors of HMG-CoA reductase to decrease the synthesis of cholesterol and possibly other products of the cholesterol biosynthesis pathway, these drugs may cause fetal harm when administered to a pregnant woman. The physiological hyperlipidemia of pregnancy does not require treatment; ^j minoxidil has been associated with hypertrichosis in the newborn infant following exposure in utero. ^k 2mg baricitinib not available in Saudi market. Abbreviations: BP: Blood Pressure, CBC: Complete Blood Count, CNS: Central Nervous System, CPK: Creatine Phosphokinase, HCG: human chorionic gonadotropin, HPA: hypothalamic-pituitary-adrenal, LFT: Liver Function Test, PUVA: Psoralen + Ultraviolet Light A, RA: Rheumatoid Arthritis, RFT: Renal Function Test, TB: Tuberculosis, HIV: human immunodeficiency virus, UA: Urinalysis, UVB: Type B Ultraviolet

References

1. Madani, S. and J. Shapiro, *Alopecia areata update*. J Am Acad Dermatol, 2000. **42**(4): p. 549-66; quiz 567-70.
2. Kurosawa, M., et al., *A comparison of the efficacy, relapse rate and side effects among three modalities of systemic corticosteroid therapy for alopecia areata*. Dermatology, 2006. **212**(4): p. 361-5.
3. Fukuyama, M., T. Ito, and M. Ohyama, *Alopecia areata: Current understanding of the pathophysiology and update on therapeutic approaches, featuring the Japanese Dermatological Association guidelines*. J Dermatol, 2022. **49**(1): p. 19-36.
4. Ito, T., et al., *Maintenance of hair follicle immune privilege is linked to prevention of NK cell attack*. J Invest Dermatol, 2008. **128**(5): p. 1196-206.
5. Ito, T., et al., *Collapse and restoration of MHC class-I-dependent immune privilege: exploiting the human hair follicle as a model*. Am J Pathol, 2004. **164**(2): p. 623-34.
6. Xing, L., et al., *Alopecia areata is driven by cytotoxic T lymphocytes and is reversed by JAK inhibition*. Nat Med, 2014. **20**(9): p. 1043-9.
7. Jahn-Bassler, K., et al., *Sequential high- and low-dose systemic corticosteroid therapy for severe childhood alopecia areata*. J Dtsch Dermatol Ges, 2017. **15**(1): p. 42-47.
8. Starace, M., et al., *Female Androgenetic Alopecia: An Update on Diagnosis and Management*. Am J Clin Dermatol, 2020. **21**(1): p. 69-84.
9. Sharma, V.K., G. Dawn, and B. Kumar, *Profile of alopecia areata in Northern India*. Int J Dermatol, 1996. **35**(1): p. 22-7.
10. Alshahrani, A.A., et al., *Prevalence and Clinical Characteristics of Alopecia Areata at a Tertiary Care Center in Saudi Arabia*. Dermatology Research and Practice, 2020. **2020**: p. 7194270.
11. Al-Ajlan, A., et al., *Prevalence of Alopecia Areata in Saudi Arabia: Cross-Sectional Descriptive Study*. Cureus, 2020. **12**(9): p. e10347.
12. Cranwell, W.C., et al., *Treatment of alopecia areata: An Australian expert consensus statement*. Australas J Dermatol, 2019. **60**(2): p. 163-170.
13. Ramos, P.M., et al., *Consensus on the treatment of alopecia areata - Brazilian Society of Dermatology*. An Bras Dermatol, 2020. **95 Suppl 1**(Suppl 1): p. 39-52.
14. Rossi, A., et al., *Italian Guidelines in diagnosis and treatment of alopecia areata*. Giornale Italiano di Dermatologia e Venereologia, 2019. **154**: p. 609-623.
15. Meah, N., et al., *The Alopecia Areata Consensus of Experts (ACE) study part II: Results of an international expert opinion on diagnosis and laboratory evaluation for alopecia areata*. J Am Acad Dermatol, 2021. **84**(6): p. 1594-1601.
16. Meah, N., et al., *The Alopecia Areata Consensus of Experts (ACE) study: Results of an international expert opinion on treatments for alopecia areata*. J Am Acad Dermatol, 2020. **83**(1): p. 123-130.
17. Olsen, E.A., et al., *Objective outcome measures: Collecting meaningful data on alopecia areata*. J Am Acad Dermatol, 2018. **79**(3): p. 470-478.e3.
18. King, B.A., et al., *Development of the alopecia areata scale for clinical use: Results of an academic-industry collaborative effort*. J Am Acad Dermatol, 2022. **86**(2): p. 359-364.
19. Wyrwich, K.W., et al., *Development of Clinician-Reported Outcome (ClinRO) and Patient-Reported Outcome (PRO) Measures for Eyebrow, Eyelash and Nail Assessment in Alopecia Areata*. American Journal of Clinical Dermatology, 2020. **21**(5): p. 725-732.
20. Olsen, E., et al., *Alopecia areata investigational assessment guidelines. National Alopecia Areata Foundation*. J Am Acad Dermatol, 1999. **40**(2 Pt 1): p. 242-6.
21. Olsen, E.A., et al., *Alopecia areata investigational assessment guidelines--Part II. National Alopecia Areata Foundation*. J Am Acad Dermatol, 2004. **51**(3): p. 440-7.

22. Ruiz-Doblado, S., A. Carrizosa, and M.J. García-Hernández, *Alopecia areata: psychiatric comorbidity and adjustment to illness*. Int J Dermatol, 2003. **42**(6): p. 434-7.
23. Koo, J.Y., et al., *Alopecia areata and increased prevalence of psychiatric disorders*. Int J Dermatol, 1994. **33**(12): p. 849-50.
24. Ghanizadeh, A., *Comorbidity of psychiatric disorders in children and adolescents with alopecia areata in a child and adolescent psychiatry clinical sample*. Int J Dermatol, 2008. **47**(11): p. 1118-20.
25. Ikeda, T., *A new classification of alopecia areata*. Dermatologica, 1965. **131**(6): p. 421-45.
26. van der Steen, P.H., et al., *Prognostic factors in the treatment of alopecia areata with diphenylcyclopropenone*. J Am Acad Dermatol, 1991. **24**(2 Pt 1): p. 227-30.
27. Tosti, A., et al., *Trachyonychia associated with alopecia areata: a clinical and pathologic study*. J Am Acad Dermatol, 1991. **25**(2 Pt 1): p. 266-70.
28. Du Vivier, A. and D.D. Munro, *Alopecia areata, autoimmunity, and Down's syndrome*. Br Med J, 1975. **1**(5951): p. 191-2.
29. Petukhova, L., et al., *Genome-wide association study in alopecia areata implicates both innate and adaptive immunity*. Nature, 2010. **466**(7302): p. 113-7.
30. Betz, R.C., et al., *Genome-wide meta-analysis in alopecia areata resolves HLA associations and reveals two new susceptibility loci*. Nat Commun, 2015. **6**: p. 5966.
31. King, B., et al., *Two Phase 3 Trials of Baricitinib for Alopecia Areata*. N Engl J Med, 2022. **386**(18): p. 1687-1699.
32. King, B., et al., *Efficacy and safety of the oral Janus kinase inhibitor baricitinib in the treatment of adults with alopecia areata: Phase 2 results from a randomized controlled study*. J Am Acad Dermatol, 2021. **85**(4): p. 847-853.
33. van der Schaar, W.W. and J.H. Sillevs Smith, *An evaluation of PUVA-therapy for alopecia areata*. Dermatologica, 1984. **168**(5): p. 250-2.
34. Herz-Ruelas, M.E., et al., *Escalating dosimetry of UVA-1 in the treatment of alopecia areata*. Int J Dermatol, 2017. **56**(6): p. 653-659.
35. Ohtsuki, A., et al., *308-nm Excimer Lamp for the Treatment of Alopecia Areata: Clinical Trial on 16 Cases*. Indian J Dermatol, 2013. **58**(4): p. 326.
36. Mlacker, S., et al., *A review on laser and light-based therapies for alopecia areata*. J Cosmet Laser Ther, 2017. **19**(2): p. 93-99.
37. Strazzulla, L.C., et al., *Alopecia areata: Disease characteristics, clinical evaluation, and new perspectives on pathogenesis*. J Am Acad Dermatol, 2018. **78**(1): p. 1-12.
38. Lamb, R.C., D. Young, and S. Holmes, *Retrospective review of diphenylcyclopropenone in the treatment of alopecia areata*. Clin Exp Dermatol, 2016. **41**(4): p. 352-8.
39. Kuin, R.A., et al., *Diphenylcyclopropenone in patients with alopecia areata. A critically appraised topic*. Br J Dermatol, 2015. **173**(4): p. 896-909.
40. Sharma, V.K. and S. Gupta, *Twice weekly 5 mg dexamethasone oral pulse in the treatment of extensive alopecia areata*. J Dermatol, 1999. **26**(9): p. 562-5.
41. Rashidi, T. and A.A. Mahd, *Treatment of persistent alopecia areata with sulfasalazine*. Int J Dermatol, 2008. **47**(8): p. 850-2.
42. Alkhalifah, A., et al., *Alopecia areata update: part II. Treatment*. J Am Acad Dermatol, 2010. **62**(2): p. 191-202, quiz 203-4.
43. Aghaei, S., *An uncontrolled, open label study of sulfasalazine in severe alopecia areata*. Indian J Dermatol Venereol Leprol, 2008. **74**(6): p. 611-3.
44. Ellis, C.N., M.F. Brown, and J.J. Voorhees, *Sulfasalazine for alopecia areata*. J Am Acad Dermatol, 2002. **46**(4): p. 541-4.

45. O'Shea, J.J., et al., *Janus kinase inhibitors in autoimmune diseases*. Ann Rheum Dis, 2013. **72 Suppl 2**(o 2): p. ii111-5.
46. King, B., et al., *Efficacy and safety of ritlecitinib in adults and adolescents with alopecia areata: a randomised, double-blind, multicentre, phase 2b–3 trial*. The Lancet, 2023. **401**(10387): p. 1518-1529.
47. Liu, L.Y., et al., *Tofacitinib for the treatment of severe alopecia areata and variants: A study of 90 patients*. J Am Acad Dermatol, 2017. **76**(1): p. 22-28.
48. Craiglow, B.G. and B.A. King, *Killing two birds with one stone: oral tofacitinib reverses alopecia universalis in a patient with plaque psoriasis*. J Invest Dermatol, 2014. **134**(12): p. 2988-2990.
49. Dhayalan, A. and B.A. King, *Tofacitinib Citrate for the Treatment of Nail Dystrophy Associated With Alopecia Universalis*. JAMA Dermatol, 2016. **152**(4): p. 492-3.
50. Mackay-Wiggan, J., et al., *Oral ruxolitinib induces hair regrowth in patients with moderate-to-severe alopecia areata*. JCI Insight, 2016. **1**(15): p. e89790.
51. Fleischmann, R., et al., *Placebo-controlled trial of tofacitinib monotherapy in rheumatoid arthritis*. N Engl J Med, 2012. **367**(6): p. 495-507.
52. European Medicines Agency. *EMA confirms measures to minimise risk of serious side effects with Janus kinase inhibitors for chronic inflammatory disorders*. 2023 [cited 2023 20 February]; Available from: <https://www.ema.europa.eu/en/news/ema-confirms-measures-minimise-risk-serious-side-effects-janus-kinase-inhibitors-chronic>.
53. Phan, K. and D.F. Sebaratnam, *JAK inhibitors for alopecia areata: a systematic review and meta-analysis*. J Eur Acad Dermatol Venereol, 2019. **33**(5): p. 850-856.
54. Phan, K., V. Ramachandran, and D.F. Sebaratnam, *Methotrexate for alopecia areata: A systematic review and meta-analysis*. J Am Acad Dermatol, 2019. **80**(1): p. 120-127.e2.
55. Lee, D., et al., *Treatment of Severe Alopecia Areata: Combination Therapy Using Systemic Cyclosporine A with Low Dose Corticosteroids*. Ann Dermatol, 2008. **20**(4): p. 172-8.
56. Jabbari, A., et al., *An Open-Label Pilot Study to Evaluate the Efficacy of Tofacitinib in Moderate to Severe Patch-Type Alopecia Areata, Totalis, and Universalis*. J Invest Dermatol, 2018. **138**(7): p. 1539-1545.
57. Wambier, C.G., B.G. Craiglow, and B.A. King, *Combination tofacitinib and oral minoxidil treatment for severe alopecia areata*. J Am Acad Dermatol, 2021. **85**(3): p. 743-745.
58. Choi, J.W., et al., *Simvastatin/Ezetimibe Therapy for Recalcitrant Alopecia Areata: An Open Prospective Study of 14 Patients*. Ann Dermatol, 2017. **29**(6): p. 755-760.
59. Cervantes, J., et al., *Treatment of Alopecia Areata with Simvastatin/Ezetimibe*. J Investig Dermatol Symp Proc, 2018. **19**(1): p. S25-S31.